


RESENTING CLINICAL SIGNS
DATE History: Murmur. Pre-anesthetic evaluation.

8/17/21 ECHOCARDIOGRAPHIC FINDINGS

2D, M-mode, and Doppler study. This exam is compared to the one performed 1/26/21.

PERFORMED BY: Left atrial size is normal. The mitral valve appears normal, though trace mitral regurgitation is present. Left ventricular dimensions are normal. Left ventricular systolic function is hyperdynamic. The aorta and aortic valve are normal. Right atrial and right ventricular dimensions are normal. The tricuspid valve appears normal. The pulmonary artery and pulmonic valve are normal. No shunting lesions are visualized. No pericardial effusion or cardiac masses are seen.

INTERPRETED BY

 Dr. Meredith Swart
 Keith Blass, DVM,
 MS, DACVIM
 (Cardiology)

 LA - 22.2 mm
 LVIDd - 18.7 mm
 LVIDs - 7.9 mm
 FS - 57.7%
 RA - 15.7 mm
 LVOT - 1.30 m/s
 RVOT - 1.08 m/s

PATIENT

Bella Ward

ASSESSMENT/RECOMMENDATIONS
SPECIES

Canine

The only potential abnormality seen in this exam is trace mitral regurgitation, which could either be a normal physiologic variant or a very early indicator of developing degenerative valve disease. The hemodynamic effects of the regurgitation are negligible, and Bella's cardiac function is well-compensated.

BREED

Chihuahua

Bella's cardiovascular risk for general anesthesia is low based on this exam, and there are no contraindications to the use of any specific anesthetic agents.

No therapy is recommended based on this exam.

SEX

FS

A recheck echocardiogram is in 9 months to evaluate for progressive mitral regurgitation.

AGE

10 y

WEIGHT

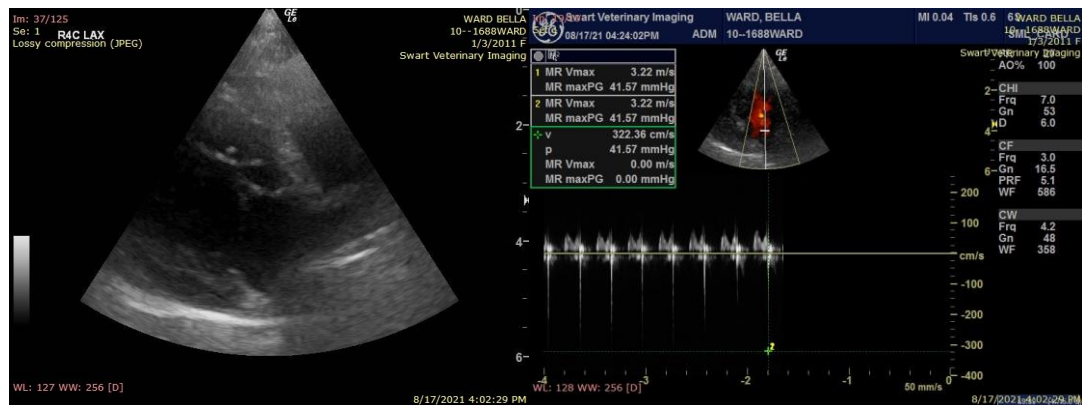
8.0 lb

HOSPITAL NAME

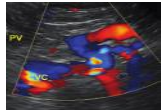
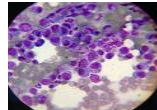
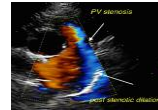
 Swart Veterinary
 Imaging

REFERRING VET

Dr. Swart



The information and recommendations provided are based on the images presented by the referring veterinarian. No evaluation can be communicated regarding pathology that was not visible in the image/video clips provided.



Thank you for this referral. If the clinical or image interpretation does not parallel your findings or if I can be of any further assistance please contact me.

DATE

8/17/21

Keith Blass, DVM, MS, DACVIM (Cardiology)
KeithBlass@gmail.com
631-804-5754

PERFORMED BY:

Dr. Meredith Swart

INTERPRETED BY

Keith Blass, DVM,
MS, DACVIM
(Cardiology)

PATIENT

Bella Ward

SPECIES

Canine

BREED

Chihuahua

SEX

FS

AGE

10 y

WEIGHT

8.0 lb

HOSPITAL NAME

Swart Veterinary
Imaging

REFERRING VET

Dr. Swart